

*Care of the Patient with*  
**Conjunctivitis**



**OPTOMETRY:  
THE PRIMARY EYE CARE PROFESSION**

Doctors of optometry are independent primary health care providers who examine, diagnose, treat, and manage diseases and disorders of the visual system, the eye, and associated structures as well as diagnose related systemic conditions.

Optometrists provide more than two-thirds of the primary eye care services in the United States. They are more widely distributed geographically than other eye care providers and are readily accessible for the delivery of eye and vision care services. There are approximately 32,000 full-time equivalent doctors of optometry currently in practice in the United States. Optometrists practice in more than 7,000 communities across the United States, serving as the sole primary eye care provider in more than 4,300 communities.

The mission of the profession of optometry is to fulfill the vision and eye care needs of the public through clinical care, research, and education, all of which enhance the quality of life.



# OPTOMETRIC CLINICAL PRACTICE GUIDELINE CARE OF THE PATIENT WITH CONJUNCTIVITIS

## Reference Guide for Clinicians

First Edition Originally Prepared by (and Second Edition Reviewed by)  
the American Optometric Association Consensus Panel on Care of the  
Patient with Conjunctivitis:

Christopher J. Quinn, O.D., Principal Author  
Dennis E. Mathews, O.D.  
Richard F. Noyes, O.D.  
Gary E. Oliver, O.D.  
J. James Thimons, Jr., O.D.  
Randall K. Thomas, O.D.

Reviewed by the AOA Clinical Guidelines Coordinating Committee:

John C. Townsend, O.D., Chair (2<sup>nd</sup> Edition)  
John F. Amos, O.D., M.S. (1<sup>st</sup> and 2<sup>nd</sup> Edition)  
Barry Barresi, O.D., Ph.D. (1<sup>st</sup> Edition)  
Kerry L. Beebe, O.D. (1<sup>st</sup> Edition)  
Jerry Cavallerano, O.D., Ph.D. (1<sup>st</sup> Edition)  
John Lahr, O.D. (1<sup>st</sup> Edition)  
W. Howard McAlister, O.D., M.P.H. (2<sup>nd</sup> Edition)  
Stephen C. Miller, O.D. (2<sup>nd</sup> Edition)  
David Mills, O.D. (1<sup>st</sup> Edition)

Approved by the AOA Board of Trustees June 22, 1995 (1<sup>st</sup> Edition) and  
November 8, 2002 (2<sup>nd</sup> Edition)

Second printing February 1996

© AMERICAN OPTOMETRIC ASSOCIATION 1995, 2002  
243 N. Lindbergh Blvd., St. Louis, MO 63141-7881

Printed in U.S.A.

NOTE: Clinicians should not rely on the Clinical  
Guideline alone for patient care and management.  
Refer to the listed references and other sources  
for a more detailed analysis and discussion of  
research and patient care information. The  
information in the Guideline is current as of the  
date of publication. It will be reviewed periodically  
and revised as needed.

**TABLE OF CONTENTS**

**INTRODUCTION** ..... 1

**I. STATEMENT OF THE PROBLEM**..... 3

**A. Description and Classification of Conjunctivitis**..... 3

        1. Allergic Conjunctivitis ..... 3

            a. Atopic Keratoconjunctivitis ..... 4

            b. Simple Allergic Conjunctivitis..... 4

            c. Seasonal Conjunctivitis ..... 4

            d. Vernal Conjunctivitis ..... 4

            e. Giant Papillary Conjunctivitis ..... 5

        2. Bacterial Conjunctivitis ..... 5

            a. Hyperacute Bacterial Conjunctivitis ..... 5

            b. Acute Bacterial Conjunctivitis ..... 5

            c. Chronic Bacterial Conjunctivitis..... 6

        3. Viral Conjunctivitis ..... 6

            a. Adenoviral Conjunctivitis ..... 6

            b. Herpetic Conjunctivitis ..... 6

        4. Chlamydial Conjunctivitis ..... 7

        5. Other Forms of Conjunctivitis ..... 7

            a. Contact Lens-Related Conjunctivitis..... 7

            b. Mechanical Conjunctivitis..... 8

            c. Traumatic Conjunctivitis..... 8

            d. Toxic Conjunctivitis..... 8

            e. Neonatal Conjunctivitis..... 8

            f. Parinaud Oculoglandular Syndrome ..... 9

            g. Phlyctenular Conjunctivitis..... 9

            h. Secondary Conjunctivitis ..... 9

**B. Epidemiology of Conjunctivitis** ..... 9

        1. Prevalence and Incidence ..... 9

        2. Risk Factors ..... 10

**C. Clinical Background of Conjunctivitis**..... 10

        1. Natural History ..... 10

        2. Common Signs, Symptoms, and Complications..... 10

            a. Allergic Conjunctivitis ..... 11

            b. Bacterial Conjunctivitis..... 11

            c. Viral Conjunctivitis..... 12

            d. Chlamydial Conjunctivitis..... 13

            e. Other Forms of Conjunctivitis..... 16

        3. Early Detection and Prevention ..... 18

**II. CARE PROCESS** ..... 21

**A. Diagnosis of Conjunctivitis**..... 21

1. Patient History ..... 21

2. Ocular Examination..... 23

    a. Visual Acuity ..... 23

    b. Neuro-Ophthalmic Screening..... 23

    c. External Examination..... 23

    d. Biomicroscopy ..... 24

    e. Tonometry ..... 25

    f. Fundus Examination..... 26

3. Supplemental Testing ..... 26

    a. Cultures, Smears, and Scrapings ..... 26

    b. Immunoassay ..... 26

    c. Conjunctival Biopsy..... 27

**B. Management of Conjunctivitis** ..... 27

    1. Basis for Treatment ..... 27

    2. Available Treatment Options..... 27

        a. Allergic Conjunctivitis ..... 27

        b. Bacterial Conjunctivitis..... 32

        c. Viral Conjunctivitis..... 34

        d. Chlamydial Conjunctivitis..... 35

        e. Contact Lens-Related Conjunctivitis..... 35

        f. Mechanical Conjunctivitis..... 36

        g. Traumatic Conjunctivitis..... 36

        h. Toxic Conjunctivitis..... 36

        i. Neonatal Conjunctivitis..... 37

        j. Parinaud Oculoglandular Syndrome ..... 38

        k. Phlyctenular Conjunctivitis..... 38

        l. Secondary Conjunctivitis ..... 38

    3. Patient Education ..... 38

    4. Prognosis and Follow-up ..... 39

**CONCLUSION** ..... 41

**III. REFERENCES** ..... 42

**IV. APPENDIX** ..... 51

    Figure 1: Optometric Management of the Patient with Conjunctivitis: A Brief Flowchart ..... 51

    Figure 2: Procedures for Obtaining Conjunctival Cultures, Smears, and Scrapings ..... 52

    Figure 3: Frequency and Composition of Evaluation and Management Visits for Conjunctivitis ..... 53

    Figure 4: ICD-9-CM Classification of Conjunctivitis ..... 55

    Abbreviations of Commonly Used Terms..... 59

    Glossary ..... 60



## **INTRODUCTION**

Optometrists, through their clinical education, training, experience, and broad geographic distribution, have the means to provide primary eye and vision care services for a significant portion of the American public and are often the first health care practitioners to examine and diagnose patients with conjunctivitis.

This Optometric Clinical Practice Guideline for the Care of the Patient with Conjunctivitis describes appropriate examination and treatment procedures for patients with conjunctivitis. It contains recommendations for timely diagnosis and treatment, and when consultation with other health care providers may be indicated. This Guideline will assist optometrists in achieving the following goals:

- Identify patients at risk of developing conjunctivitis
- Accurately diagnose conjunctivitis of diverse origins
- Improve the quality of care rendered to patients with conjunctivitis
- Initiate appropriate treatment for conjunctivitis
- Reduce the potentially adverse effects of conjunctivitis
- Inform and educate patients and other health care providers about the diagnosis, treatment, and management of conjunctivitis.



## **I. STATEMENT OF THE PROBLEM**

Conjunctivitis is a nonspecific term used to describe an inflammation of the conjunctiva, which can be caused by a wide range of conditions. It is commonly referred to as "red eye" or "pink eye." Conjunctivitis may result from primary involvement of the conjunctival tissue or may occur secondary to other ocular or systemic conditions that produce conjunctival inflammation. Conjunctivitis is treated almost exclusively on an outpatient basis. However, infants with neonatal conjunctivitis (ophthalmia neonatorum) are generally treated as inpatients.

Although the socioeconomic cost of conjunctivitis has not been estimated, due to its relatively common occurrence, the cost may be substantial. The need for professional diagnosis and treatment, the cost of pharmaceutical intervention, lost productivity in the workplace, and loss of educational opportunity for school-age children are all factors contributing to the socioeconomic impact of conjunctivitis. Accurate diagnosis and appropriate treatment can minimize these costs and the patient's suffering. Misdiagnosis of conjunctivitis can add a substantial cost burden and may result in serious impairment of vision.

### **A. Description and Classification of Conjunctivitis**

Conjunctivitis is an inflammation of the conjunctiva. It is most commonly characterized by conjunctival hyperemia and ocular discharge. Conjunctivitis can be classified clinically according to the underlying cause. (See Appendix Figure 4 for the ICD-9-CM classification of conjunctivitis.)

#### **1. Allergic Conjunctivitis**

The conjunctiva, which has a rich vascular supply, abundant immune mediators, and direct exposure to the environment, is often involved in immune-mediated and allergic reactions. The various effects of these reactions are responsible for the signs and symptoms present in patients with allergic conjunctivitis. The major categories of allergic conjunctivitis involve type 1 hypersensitivity reactions in which the allergen reacts with IgE antibodies, stimulating mast cell degranulation and the release of

## **4 Conjunctivitis**

performed inflammatory mediators.<sup>1</sup> The types of allergic conjunctivitis include atopic keratoconjunctivitis, simple allergic conjunctivitis, seasonal or perennial conjunctivitis, vernal conjunctivitis, and giant papillary conjunctivitis.

### **a. Atopic Keratoconjunctivitis**

A severe, chronic external ocular inflammation associated with atopic dermatitis,<sup>2</sup> atopic keratoconjunctivitis (AKC) may appear late in the teenage years and continue for 4–5 decades, at which time the disease may resolve spontaneously.<sup>3</sup>

### **b. Simple Allergic Conjunctivitis**

Occurring as the result of exposure to a wide variety of allergens, simple allergic conjunctivitis often results from exposure to eye medications or contact lens solutions (or their preservatives).

### **c. Seasonal Conjunctivitis**

Examples of simple allergic conjunctivitis include both seasonal and perennial conjunctivitis. These are recurrent, usually transient, and self-limiting conditions due to seasonal exposure to ragweed, pollens, dander, dust, or mold spores.

### **d. Vernal Conjunctivitis**

Vernal conjunctivitis is a severe conjunctival inflammation that can have corneal complications. The majority of affected patients are males under the age of 20 years.<sup>4</sup> The average duration of vernal conjunctivitis is 4 years, and most patients tend to "outgrow" the condition by age 30.<sup>5</sup> The disease is more common in dry, warm climates. In more temperate climates, vernal conjunctivitis tends to be seasonal, with symptoms increasing in the spring and decreasing in the fall.<sup>6</sup>

**e. Giant Papillary Conjunctivitis**

Most often associated with soft contact lens wear, giant papillary conjunctivitis (GPC) has been reported in patients wearing soft, hard, and rigid gas-permeable contact lenses, as well as in patients with ocular prostheses or exposed sutures in contact with the conjunctiva.<sup>7,8</sup>

**2. Bacterial Conjunctivitis**

Although the ocular surface resists bacterial infection through a variety of mechanisms, conjunctival infection can occur when an organism is able to overcome the host's resistance. Host resistance can be impaired in disease states, in immunocompromised patients, or following trauma. Most common bacterial pathogens can cause conjunctivitis. These pathogens include Staphylococcus species, Haemophilus species, Streptococcus pneumoniae, and Moraxella species. Streptococcus and Haemophilus infections occur more frequently in children.<sup>9</sup> Bacterial conjunctivitis can be classified as hyperacute, acute, and chronic.

**a. Hyperacute Bacterial Conjunctivitis**

Hyperacute (purulent) bacterial conjunctivitis is commonly caused by Neisseria gonorrhoeae, microorganisms that can penetrate an intact corneal epithelium, or, less frequently, by Neisseria meningitidis. Other bacteria that are less common causes of hyperacute conjunctivitis include Staphylococcus aureus, Streptococcus species, Haemophilus species, and Pseudomonas aeruginosa.<sup>10,11</sup>

Most commonly acquired by autoinoculation from infected genitalia and most often seen in neonates, adolescents, and young adults, hyperacute bacterial conjunctivitis may also be more common during warmer months of the year.<sup>12</sup>

**b. Acute Bacterial Conjunctivitis**

A common infectious condition that can affect all ages and races and both genders, acute (mucopurulent) bacterial conjunctivitis is caused by a number of microbial agents, primarily Staphylococcus aureus,

**6. Conjunctivitis**

Streptococcus pneumoniae, and Haemophilus species. The condition is self-limiting, generally lasting less than 3 weeks.

**c. Chronic Bacterial Conjunctivitis**

Bacterial conjunctivitis lasting longer than 4 weeks can be considered chronic and usually has a different etiology than acute bacterial conjunctivitis. Chronic bacterial conjunctivitis is frequently associated with continuous inoculation of bacteria associated with blepharitis. The most common cause of chronic bacterial conjunctivitis is Staphylococcus aureus. Angular blepharoconjunctivitis can result from chronic staphylococcal or Moraxella infections.

**3. Viral Conjunctivitis**

A wide variety of viruses can cause conjunctivitis. Many of these infections are mild, transient, and self-limiting. Some causes of viral conjunctivitis can have significant symptoms. The most common viruses associated with conjunctivitis are adenovirus and herpesvirus.

**a. Adenoviral Conjunctivitis**

Among more than 47 identified serotypes of adenovirus,<sup>13</sup> many can cause conjunctivitis. Adenoviral infections occur worldwide and probably represent the most common external ocular infection.<sup>14</sup> Epidemic outbreaks are often classified as the clinical syndromes of epidemic keratoconjunctivitis (EKC) or pharyngeal conjunctival fever (PCF). EKC, which often occurs in adults aged 20–40 years, affects men and women equally. Race, social status, and nutritional status are not considered risk factors for the disease.<sup>15</sup> PCF occurs more commonly in children and is usually accompanied by mild pharyngitis and low-grade fever. Adenoviral infections can be highly contagious.

**b. Herpetic Conjunctivitis**

Infection with a member of the Herpesvirus genus (e.g., herpes simplex, varicella-zoster, or Epstein-Barr virus) can result in acute conjunctivitis. The herpes simplex virus (Herpesvirus hominis) is an important ocular



## Statement of the Problem 7

pathogen and the leading cause of blindness from corneal disease in the United States.<sup>16</sup> Between 70 and 90 percent of the population show serologic evidence of previous herpes simplex virus infection by the age of 15 years, and 97 percent by age 60.<sup>17</sup> Although most cases of primary herpes infection are subclinical, the diagnosis should be considered for all young patients who have acute conjunctivitis.

Herpes zoster is a recurrent Herpesvirus varicellae infection. It usually affects middle-aged or older patients, both genders equally, and shows no seasonal or racial predilection.<sup>18</sup> Fifty percent of patients with herpes zoster ophthalmicus (involving the ophthalmic division of the trigeminal nerve) show involvement of the ocular structures, of which conjunctivitis is the most common manifestation.<sup>19</sup>

### **4. Chlamydial Conjunctivitis**

Chlamydiae are obligate intracellular parasites that rank among the more important causes of conjunctivitis. Chlamydia trachomatis is the causative agent in the most common sexually transmitted disease in the United States,<sup>20</sup> and it can be accompanied by conjunctivitis. Ocular infection from C. trachomatis may result in adult inclusion conjunctivitis, ophthalmia neonatorum, trachoma, or lymphogranuloma venereum.

Adult inclusion conjunctivitis results from exposure to infective genital tract discharge. The disease is transmitted by autoinoculation from the genital tract or by genital-to-eye inoculation from an infected sexual partner. Adult inclusion conjunctivitis is most common in young, sexually active adults and in population groups with high venereal disease rates.<sup>21</sup>

### **5. Other Forms of Conjunctivitis**

#### ***a. Contact Lens-Related Conjunctivitis***

Contact lens wear can cause a variety of secondary conjunctivitis conditions. Complications of contact lens wear can be acute or chronic, allergic or nonallergic in origin.<sup>8</sup> Characteristics of the conjunctivitis vary with the underlying mechanism. The most common types of noninfectious

## 8. Conjunctivitis

conjunctivitis associated with contact lens wear are related to solution allergy, tissue hypoxia, or GPC.

#### ***b. Mechanical Conjunctivitis***

Mechanical irritation of the conjunctival surface can result in secondary conjunctivitis. Common causes of mechanical conjunctivitis include eyelashes (entropion, trichiasis, or misdirected lashes), sutures, foreign bodies, and conjunctival concretions.

#### ***c. Traumatic Conjunctivitis***

Conjunctival trauma, either direct injury (e.g., abrasions, lacerations, or epithelial defects) or indirect trauma (e.g., chemical injury) may result in the clinical manifestations of conjunctivitis.

#### ***d. Toxic Conjunctivitis***

Toxic conjunctivitis may occur following the administration of drugs or exposure to noxious chemicals. Molluscum contagiosum lesions of the periorbital skin can cause a secondary toxic follicular conjunctivitis.

#### ***e. Neonatal Conjunctivitis***

Ophthalmia neonatorum is a name for conjunctivitis that occurs within the first month of life. Among many different causes of neonatal conjunctivitis, the common etiologic agents are chemical, chlamydial, bacterial (e.g., Neisseria gonorrhoeae), and herpetic. The introduction of Crede's (silver nitrate) prophylaxis in 1881 dramatically reduced the incidence of gonococcal neonatal conjunctivitis.<sup>22</sup> Since the 1970's, topical ophthalmic tetracycline, erythromycin, and povidine iodine 2.5% have been substituted for silver nitrate, with equal effectiveness;<sup>23</sup> however, none of these treatment options effectively reduces the rate of chlamydial infection.<sup>24</sup>



**f. Parinaud Oculoglandular Syndrome**

A broad category generally used to describe granulomatous conjunctivitis, Parinaud oculoglandular syndrome is caused by a wide range of infectious agents. Cat-scratch disease is the most common cause of Parinaud oculoglandular syndrome.<sup>25</sup>

**g. Phlyctenular Conjunctivitis**

A delayed hypersensitivity reaction to the introduction of foreign proteins can lead to phlyctenular conjunctivitis.<sup>26</sup> Though historically associated with tuberculo-protein sensitivity, phlyctenular conjunctivitis is now most commonly associated with staphylococcal infection.<sup>26,27</sup>

**h. Secondary Conjunctivitis**

Conjunctivitis can be associated with a variety of ocular and systemic disorders that include:

- Keratoconjunctivitis sicca
- Blepharitis
- Reiter's syndrome
- Cicatricial pemphigoid
- Erythema multiforme (Stevens-Johnson syndrome)
- Relapsing polychondritis
- Lyme disease
- Superior limbic keratoconjunctivitis
- Floppy lid syndrome
- Mucous fishing syndrome
- Collagen-vascular diseases
- Sarcoidosis.

**B. Epidemiology of Conjunctivitis**

**1. Prevalence and Incidence**

Conjunctivitis has worldwide distribution, affecting persons of all ages, races, social strata, and both genders. In the United States, its prevalence in the population ages 1–74 was 13 in 1,000, according to the National Health Survey conducted in 1971–1972.<sup>29</sup> Although there are no reliable figures documenting the incidence of conjunctivitis, it is estimated to be one of the most common ophthalmic maladies.<sup>30</sup>

**2. Risk Factors**

Most cases of infection-associated conjunctivitis are sporadic or related to epidemic outbreaks. The specific risk factors for its development are ill defined and related to the underlying etiology. Patients need to take steps to limit the spread of infectious forms of conjunctivitis to others. Following good hygiene practices and limiting direct personal contact can reduce the potential for transmission of the infection.

**C. Clinical Background of Conjunctivitis**

**1. Natural History**

The natural history of conjunctivitis varies with the causative agent. Many cases of primary conjunctivitis are self-limiting and resolve without treatment. Although conjunctivitis is not a major cause of ocular morbidity or vision loss in the United States, it can cause serious, permanent damage to the eye. In fact, conjunctivitis has been reported as the initial manifestation of an ultimately fatal systemic infection.<sup>31</sup> Patients who have undergone glaucoma-filtering surgery and who develop bacterial conjunctivitis are at increased risk of developing endophthalmitis. Inadequately treated gonococcal conjunctivitis can progress to keratitis, endophthalmitis, and blindness.<sup>32,33</sup> Chlamydial ophthalmia neonatorum can be associated with chlamydial pneumonitis.<sup>34,35</sup> Membranous conjunctivitis and conjunctivitis with secondary conjunctival scarring may lead to keratitis sicca, symblepharon formation, trichiasis, and corneal scarring with resultant blindness.

**2. Common Signs, Symptoms, and Complications**

The various forms of conjunctivitis are characterized by the following signs and symptoms, which are summarized in Table 1.





## Statement of the Problem 11

### a. *Allergic Conjunctivitis*

- **Atopic keratoconjunctivitis.** Bilateral, hyperemic, and chemotic bulbar conjunctiva, mucous discharge, and severe itching in patients with a history of atopy.
- **Simple allergic conjunctivitis.** Unilateral or bilateral, mild to moderate conjunctival hyperemia, and chemosis. Symptoms include itching and tearing in response to antigen exposure.
- **Seasonal conjunctivitis.** Seasonal and recurrent episodes of mild bilateral conjunctival hyperemia, chemosis, and papillary response. Patients experience mild to moderate itching, tearing, and a mucoid discharge in response to environmental antigen exposure (e.g., pollen).
- **Vernal conjunctivitis.** Severe bilateral itching and copious, rope-like, mucous discharge. In the palpebral form of vernal conjunctivitis, the upper tarsal conjunctiva has giant papillae. In the less common limbal form, the development of a gelatinous thickening of the superior limbal conjunctiva occurs, and distinct nodules can sometimes be observed within the thickened limbal area. Trantas' dots (small white dots composed of eosinophilic concretions) on the surface of the thickened conjunctiva are pathognomonic of limbal vernal conjunctivitis.
- **Giant papillary conjunctivitis.** Mild bilateral hyperemia, mucous discharge, and itching. In contact lens wearers, symptoms include decreased lens tolerance or wearing time and increased lens movement with blinking. Examination of the superior tarsal conjunctiva reveals papillary hypertrophy.

### b. *Bacterial Conjunctivitis*

- **Hyperacute bacterial conjunctivitis.** Rapid onset of copious purulent discharge, severe conjunctival hyperemia, conjunctival chemosis, and lid edema. The conjunctivitis may be unilateral or

## 12 Conjunctivitis

bilateral, accompanied by pain, globe tenderness, and preauricular lymphadenopathy.

- **Acute bacterial conjunctivitis.** Acute onset of unilateral discharge, irritation, and diffuse conjunctival hyperemia. The tarsal conjunctiva usually features a papillary response. Mucopurulent/purulent discharge is common in acute bacterial conjunctivitis; preauricular lymphadenopathy is generally absent. The fellow eye typically becomes involved within 48 hours. In children 6 months to 3 years old, conjunctivitis accompanied by bluish discoloration and swelling of the periorbital skin suggests potential progression to orbital cellulitis from a Haemophilus influenzae infection. This infection, which may be associated with fever and upper respiratory tract infection, can progress to include septicemia, metastatic meningitis, septic arthritis, or endophthalmitis.<sup>36,37</sup>
  - **Chronic bacterial conjunctivitis.** A variety of nonspecific symptoms and clinical findings. Patients often experience chronic (longer than 4-week) irritation, foreign body sensation, and low-grade conjunctival hyperemia. A papillary or follicular reaction can occur, and mucoid discharge may be present. Chronic conjunctivitis is often accompanied by lid hyperemia and eyelid crusting that are typically present in the morning.
- ### c. *Viral Conjunctivitis*
- **Adenoviral conjunctivitis.** Acute onset of unilateral, then bilateral, bulbar and palpebral conjunctival hyperemia, tearing, and inferior tarsal and fornix conjunctival follicular response. Petechial hemorrhages are commonly present, particularly in the bulbar conjunctiva. Depending on the stage of development, the patient may manifest a diffuse pattern of punctate keratitis in addition to the conjunctival signs. The keratitis may be followed by the development of multiple corneal subepithelial infiltrates. Conjunctival pseudomembranes may be found on the superior or inferior tarsal conjunctiva. Lid edema may also be present. A

Statement of the Problem 13

common associated finding, preauricular lymphadenopathy, is often more prominent on the side of the eye initially affected.

- **Herpetic conjunctivitis.** Lid edema, conjunctival hyperemia, and occasional pseudomembrane formation. Dendritic or geographic ulceration sometimes occurs on the conjunctival surface. Characteristic herpetic dermatologic manifestations (vesicular eruptions) may be observed on the lids or the periorbital skin.
- d. **Chlamydial Conjunctivitis**
- **Adult inclusion conjunctivitis.** Large follicles, predominantly in the lower palpebral and fornix conjunctiva. The conjunctiva is often hyperemic, and a mild mucoid discharge is commonly present. Occasionally there is preauricular lymphadenopathy and lid edema, especially early in the course of the infection.

14 Conjunctivitis

**Table 1**  
**Signs and Symptoms of Common Types of Conjunctivitis**

Etiology	Condition	Onset/ Duration	Symptoms
Bacterial	Hyperacute bacterial	Acute	Purulent discharge, sometimes pain
	Acute bacterial	Acute	Tearing, lid crusting
	Chronic bacterial	Chronic	Lid crusting, foreign body sensation
Viral	Adenoviral	Acute	Tearing, lid crusting upon awakening
	Herpetic	Acute	Tearing
Allergic	Seasonal	Seasonal/ recurrent	Itching, tearing
	Vernal	Seasonal/ chronic	Itching, mucous discharge
	Giant papillary	Acute/ chronic	Itching, contact lens intolerance, mucous discharge
Chlamydial	Chlamydial	Acute/ Chronic	Tearing

**Table 1 (Continued)**

<b>Etiology</b>	<b>Conjunctival Response</b>	<b>Preauricular Lymphadenopathy</b>	<b>Discharge</b>
Bacterial	Intense diffuse hyperemia, papillae	Occasional	Copious purulent
	Moderate diffuse hyperemia, papillae	Unusual	Purulent-mucopurulent
	Low-grade hyperemia, mixed follicles/papillae	Unusual	Mucopurulent
Viral	Diffuse hyperemia, petechial hemorrhages, follicle	Common	Serous, serous-mucoid, or mucopurulent
	Diffuse hyperemia, follicles	Occasional	Serous-mucoid
Allergic	Mild hyperemia, mixed papillae/follicles	Unusual	Mucoid
	Tranta's dots – limbal Giant papillae – tarsal	Unusual	Ropey mucoid
	Giant papillae	Unusual	Mucoid
Chlamydial	Diffuse hyperemia, giant follicles, predominantly inferiorly	Occasional	Mucoid

*e. Other Forms of Conjunctivitis*

- **Contact lens-related conjunctivitis.** Mild itching and hyperemia, mucous discharge, and abnormal thickening of the conjunctiva in one or both eyes.
- **Mechanical conjunctivitis.** Focal or diffuse conjunctival hyperemia, foreign body sensation, and tearing.
- **Traumatic conjunctivitis.** Conjunctival hyperemia, tearing, and foreign body sensation.
- **Toxic conjunctivitis.** Unilateral or bilateral conjunctival hyperemia and a mixed follicular/papillary reaction of the tarsal conjunctiva.
- **Neonatal conjunctivitis.** Diffuse hyperemia and other clinical manifestations that vary with the etiology of the disease (Table 2).



**Table 2**  
**Common Etiologic Agents and Clinical Manifestations**  
**of Neonatal Conjunctivitis**

<b>Etiologic Agent</b>	<b>Onset</b>	<b>Conjunctival Features</b>	<b>Cytology</b>
Chemical	24 hours	Diffuse hyperemia, purulent exudate	Polymorphonuclear lymphocytes
Chlamydial	5–10 days	Diffuse hyperemia, purulent exudate	Basophilic cytoplasmic inclusion bodies
Other bacterial	5 days	Diffuse hyperemia, mucopurulent discharge	Causative agent
<u>Neisseria gonorrhoeae</u>	3–5 days	Hyperacute conjunctivitis with mucopurulent discharge	Intraepithelial Gram-negative diplococci
Herpetic	5–15 days	Diffuse hyperemia, watery discharge	Multinucleated giant cells

*18 Conjunctivitis*

- **Parinaud oculoglandular conjunctivitis.** Usually unilateral and accompanied by ipsilateral regional lymphadenopathy. Conjunctival granulomas or ulcerations are often present.
- **Phlyctenular conjunctivitis.** Unilateral and often sectorial conjunctival hyperemia, with the development of an elevated and sometimes ulcerated nodule on the conjunctival surface. Patients may experience pain, tearing, and photophobia, especially when there is corneal involvement.
- **Secondary conjunctivitis.** Associated with other ocular and systemic disorders, often nonspecific, with bulbar conjunctival hyperemia and tearing. Because "dry eye syndrome" is a common cause of noninfectious chronic conjunctivitis, it should be ruled out prior to initiating therapy.

Complications associated with conjunctivitis are related to its etiology. Acute forms of bacterial conjunctivitis can lead to symblepharon and conjunctival scarring; hyperacute forms of bacterial conjunctivitis should be monitored closely for the development of bacterial keratitis. Toxic, irritative conjunctivitis, especially when the cause is unknown, has the potential to become chronic.

**3. Early Detection and Prevention**

Primary infectious conjunctivitis occurs sporadically as a result of exposure to pathogens from direct hand-to-eye contact, exposure to airborne pathogens, sexual transmission, or contact with contaminated ophthalmic instruments. Because adenoviruses have been recovered from nonporous surfaces for up to 49 days, improperly disinfected tonometer tips are a potential source of infection.<sup>38</sup>

Preventing the spread of infectious conjunctivitis involves both adequate infection control and comprehensive patient education. Careful attention to infection control procedures in the practitioner's office helps prevent the transmission of infection. Standard infection control practices during the examination of patients with acute conjunctivitis should include barrier protection (e.g., latex gloves), hand-washing before and after the



Statement of the Problem 19

examination, and proper techniques for disinfection or sterilization of all equipment. The adoption of appropriate infection control procedures is mandatory for all practices.<sup>39</sup>



**II. CARE PROCESS**

This Guideline describes the proper care provided to a patient with conjunctivitis. The components of patient care described are not intended to be all inclusive, because professional judgment and individual patient symptoms and findings may have a significant impact on the nature, extent, and course of the services provided. Some components of care may be delegated.

**A. Diagnosis of Conjunctivitis**

A detailed examination should be performed on patients presenting with acute or chronic conjunctivitis. Additional testing is usually not necessary to diagnose routine cases of conjunctivitis. A comprehensive eye examination\* with dilation of the pupils should be performed in those patients with conjunctival hyperemia accompanied by proptosis, optic nerve dysfunction, decreased visual acuity, diplopia, or evidence of anterior chamber inflammation. Visual field testing also may be indicated for these patients.

**1. Patient History**

The diversity of etiologies for conjunctivitis makes a detailed patient history the most important step in the differential diagnosis of conjunctivitis. The patient history includes the chief complaint, ocular history, general health history and review of systems, social history, and family ocular and medical history (Table 3).

\* Refer to the Optometric Clinical Practice Guidelines, Comprehensive Adult Eye and Vision Examination or Pediatric Eye and Vision Examination, as appropriate.

**Table 3  
Components of History for Patients with Conjunctivitis**

Chief complaint	Symptoms: itching, burning, tearing, discharge, pain, foreign body sensation, photophobia Onset and course: acute vs. chronic; progressive vs. stationary Unilateral or bilateral Characteristics of discharge: purulent, mucous, serous, mixed
Ocular history	Previous episodes Prior exposure to infected individuals Trauma Contact lens wear Use of topical legend or over-the-counter medications or cosmetics
General health history	Recent upper respiratory infections Autoimmune disorders Atopy Dermatologic conditions Sexually transmitted diseases Review of systems
Social history	Environmental exposure Sexual history (as indicated)
Family history	Ocular history Medical history



**2. Ocular Examination**

The ocular examination may include, but is not limited to, the following procedures:

**a. Visual Acuity**

Conjunctivitis usually does not significantly affect visual acuity, except in cases of corneal involvement. Documentation of baseline best corrected visual acuity is standard practice.

**b. Neuro-Ophthalmic Screening**

Pupillary responses, confrontation visual fields, and extraocular motility should be evaluated in patients with conjunctivitis because several important ophthalmic disorders can masquerade as conjunctivitis. These conditions may include, but are not limited to, angle closure glaucoma, uveitis, keratitis, Graves' disease, carotid cavernous fistula, orbital pseudotumors, dacryocystitis, and canaliculitis.

**c. External Examination**

Successful diagnosis of conjunctivitis requires complete examination of the external eye and regional anatomy. Table 4 lists the important components and relevant clinical findings of the external examination.

**Table 4  
Relevant Clinical Findings in External Examination  
of Patients With Conjunctivitis**

Skin of lids and face	Acne rosacea, seborrhea, eczema, psoriasis, other dermatosis
Eyelids	Edema, ecchymosis, discoloration, ectropion, entropion, trichiasis, misdirected lashes, ulcers, eruptions, erythema, tumors, scaling, lagophthalmos, lid laxity, blepharitis, molluscum lesions, lid retraction
Globe	Proptosis, endophthalmos, displacement
Conjunctiva	Pattern of hyperemia: diffuse, focal, superior, inferior, circumlimbal, intrapalpebral, bulbar, palpebral Characteristics of discharge: purulent, mucopurulent, mucous, serous
Regional Lymphadenopathy	Preauricular, submandibular, cervical nodes

**d. Biomicroscopy**

Careful biomicroscopy should be performed on all patients with conjunctivitis. Table 5 lists the important biomicroscopic clinical observations in diagnosing patients with conjunctivitis.





**Table 5**  
**Relevant Clinical Observations in the Biomicroscopic**  
**Evaluation of Patients With Conjunctivitis**

Eyelids	Blepharitis, crusting, collarettes, meibomian gland orifices, ulcers, lid-globe apposition, tear meniscus, lashes, puncta
Bulbar conjunctiva	Hyperemia, follicles, cysts, phlyctenules, pinguecula, chemosis, hemorrhages, abrasions, ulcers, foreign bodies, lacerations, pterygium
Tarsal conjunctiva (upper and lower)	Papillae, follicles, foreign bodies, membranes, abrasions, ulcers, granulomas, symblepharon, concretions, chemosis, scarring
Cornea	Abrasions, erosions, infiltrates, ulcers, foreign bodies, punctate keratitis, pannus, dellen, keratic precipitates, dystrophies
Anterior chamber/iris/lens	Cell and flare, rubeosis iridis, hypermature cataract, chamber depth, angle anatomy, iris nodules

**e. Tonometry**

In cases that have clinical evidence of infectious conjunctivitis but no evidence of acute angle closure glaucoma or prior history of glaucoma, tonometry may be deferred until a follow-up examination.

**f. Fundus Examination**

Fundus evaluation is recommended for all patients with conjunctivitis. Dilated fundus examination is not required at the presenting examination unless specifically indicated.

**3. Supplemental Testing**

**a. Cultures, Smears, and Scrapings**

Conjunctival cultures and smears or scrapings should be obtained in cases of chronic, neonatal, hyperacute, or recurrent conjunctivitis. They should also be considered for cases in which acute conjunctivitis is unresponsive to treatment and for immunocompromised patients. Appendix Figure 2 describes procedures for obtaining conjunctival cultures, smears, and scrapings.

Hyperacute conjunctivitis has the potential for serious and blinding complications. Identification of the etiologic agent and determination of antibiotic sensitivities are essential for proper management. Cultures, smears, and scrapings, which should be obtained prior to beginning treatment, can help guide the selection of the initial treatment regime.

Cultures, smears, and scrapings are extremely helpful in the diagnosis of chronic or recurrent conjunctivitis. Conjunctival scrapings, which are needed for detailed examination of conjunctival epithelial cells and identification of intracellular inclusions, may also reveal the nature of the inflammatory cell response.

**b. Immunoassay**

Direct fluorescein-conjugated monoclonal antibody tests are used to detect chlamydial antigens in conjunctival scrapings. Commercially available through medical suppliers and laboratories, these in-office tests are easy to use, and they are highly sensitive and specific in the identification of chlamydial conjunctivitis.<sup>40</sup>

**c. Conjunctival Biopsy**

Conjunctival biopsy is occasionally useful in refractory or atypical conjunctivitis and is mandatory in cases of suspected neoplasm.

**B. Management of Conjunctivitis**

The extent to which an optometrist can provide treatment for conjunctivitis may vary with state optometry practice acts as well as the individual optometrist's credentials. (See Appendix Figure 1 for a flowchart of the management of patients diagnosed with conjunctivitis.)

**1. Basis for Treatment**

Treatment for conjunctivitis should be initiated to increase patient comfort, reduce the infection, and help prevent the spread of infection. Treatment can help reduce the socioeconomic cost of conjunctivitis and reduce the incidence of associated adverse complications in untreated cases.

**2. Available Treatment Options**

**a. Allergic Conjunctivitis**

The treatment of allergic conjunctivitis is based upon identification of specific antigens and elimination of specific pathogens, when practical, and upon the use of medications that decrease or mediate the immune response. The use of supportive treatment, including unpreserved lubricants and cold compresses, may provide symptomatic relief. A variety of pharmacologic agents\* are available to help decrease the host response and interrupt the inflammatory cascade (Table 6). The following agents are useful in treating allergic conjunctivitis:

---

\* Every effort has been made to ensure the drug dosage recommendations are accurate at the time of publication of the Guideline. However, as treatment recommendations change due to continuing research and clinical experience, clinicians should verify drug dosage schedules with information found on product information sheets.

- **Topical steroids.** Corticosteroids inhibit the inflammatory process (e.g., edema, capillary dilation, and fibroblast proliferation). They also curtail the migration of macrophages and neutrophils to inflamed areas as well as block phospholipase A2 activity and subsequent induction of the arachidonic acid cascade.<sup>41</sup> Widely employed in the treatment of acute ocular allergic disease, steroids are effective in relieving the acute symptoms of allergy; however, their use should be limited to the acute suppression of symptoms because of the potential for adverse side effects with their protracted use. Chronic use of topical corticosteroids can result in well-documented associated complications: posterior subcapsular cataract formation and elevated intraocular pressure (IOP).<sup>42</sup>

Newly developed “site-specific” steroids have been designed to reduce the complications associated with topical steroid use. Loteprednol etabonate 0.5% is effective as a treatment for GPC and as prophylaxis for seasonal allergic conjunctivitis.<sup>43,44</sup> The 0.2% concentration of loteprednol is also effective in the treatment of seasonal allergic conjunctivitis.<sup>45</sup> Both concentrations of loteprednol have a very low propensity to result in elevated IOP.<sup>46</sup>

- **Topical vasoconstrictor/antihistamines.** These agents cause vascular constriction, decrease vascular permeability, and reduce ocular itching by blocking H1 histamine receptors.<sup>47</sup>
- **Topical antihistamines.** Antihistamines competitively bind with histamine receptor sites and reduce itching and vasodilation. Levocabastine hydrochloride 0.05%, a topical selective H1 histamine receptor antagonist, is effective in relieving the signs and symptoms of allergic conjunctivitis.<sup>48</sup> Another selective H1 antagonist, azelastine hydrochloride 0.05%, is effective in reducing the symptoms associated with allergic conjunctivitis.<sup>49</sup> Emedastine difumarate 0.05%, a selective H1 antagonist, may be more efficacious than levocabastine in reducing chemosis, eyelid swelling, and other signs and symptoms associated with seasonal allergic conjunctivitis in both adult and pediatric patients.<sup>50,51</sup>



- **Topical non-steroidal anti-inflammatory drugs (NSAIDs).** These drugs inhibit the activity of cyclo-oxygenase, one of the enzymes responsible for conversion of arachidonic acid into prostaglandins.<sup>52</sup> Ketorolac tromethamine 0.5% and diclofenac sodium 0.1% are effective in reducing the signs and symptoms associated with allergic conjunctivitis,<sup>53,54</sup> although the Food and Drug Administration (FDA) has approved only ketorolac for the treatment of allergic conjunctivitis.
- **Topical mast cell stabilizers.** These agents inhibit the degranulation of mast cells, thus limiting the release of inflammatory mediators, including histamine, neutrophil and eosinophil chemotactic factors, and platelet-activating factor. Nedocromil 2%, an effective treatment for seasonal allergic conjunctivitis,<sup>55</sup> is more effective than cromolyn sodium 4.0% in treating vernal conjunctivitis.<sup>56</sup> Though less effective than fluometholone 0.1% in treating severe vernal keratoconjunctivitis, nedocromil has fewer side effects.<sup>57</sup> Lodoxamide tromethamine 0.1% has demonstrated a greater improvement in the signs and symptoms of allergic eye disease, including vernal keratoconjunctivitis, than cromolyn sodium 4.0%.<sup>58,59</sup> Pemirolast 0.1% has FDA approval as a treatment to relieve the itching associated with allergic conjunctivitis. Improved contact lens hygiene and decreased wearing time, combined with lubrication or the application of a topical mast cell stabilizing agent, or both, can help in managing symptomatic GPC.<sup>60</sup>
- **Agents with multiple mechanisms of action.** Olopatidine hydrochloride 0.1% is a selective H1 histamine antagonist that also has mast cell-stabilizing properties. Effective in reducing the signs and symptoms of allergic conjunctivitis,<sup>61</sup> olopatidine may be more effective than other mast cell-stabilizing agents in targeting the subtype of mast cell found in the conjunctiva.<sup>62</sup> Ketotifen fumarate 0.025% is also a mast cell stabilizer that acts as a histamine antagonist. Compared with ketorolac or ketotifen, olopatidine is more effective in relieving the itching and redness associated with acute allergic conjunctivitis.<sup>63-65</sup>

- **Immunosuppressants.** Cyclosporin A is a potent systemic immunosuppressant agent used to treat a variety of immune-mediated conditions. Systemically administered cyclosporin A may be an effective treatment for patients with severe atopic keratoconjunctivitis.<sup>66</sup> A topically prepared solution of cyclosporin A 2% is an alternative to topical steroids for treatment of patients with severe atopic keratoconjunctivitis.<sup>67</sup> Topical cyclosporin A has also been reported to benefit patients with vernal keratoconjunctivitis in whom conventional therapy has failed.<sup>68</sup>
- **Systemic antihistamines.** These agents are useful in certain cases of allergic response with associated lid edema, dermatitis, rhinitis, or sinusitis.<sup>69</sup> They should be used with care because of the sedating and anticholinergic effects of some first-generation antihistamine drugs. Patients should be warned of these potential side effects. Newer antihistamines are much less likely to cause sedation, but their use may result in increased ocular surface dryness.

**Table 6**  
**Agents for the Treatment of Allergic Conjunctivitis**

<b>Type of Pharmaceutical Agent</b>	<b>Concentration</b>	<b>Frequency of Administration</b>
<i>Steroidal anti-inflammatory</i>		
Dexamethasone	0.1% suspension and solution	Variable
Fluorometholone acetate	0.1% suspension	Variable
Fluorometholone alcohol	0.1% suspension	Variable
Loteprednol etabonate	0.2%–0.5% suspension	Variable
Medrysone	1.0% suspension	Variable
Prednisolone acetate	0.12–1.0% suspension	Variable
Prednisolone sodium phosphate	0.125–1.0% solution	Variable
Rimexolone	1.0% suspension	Variable
<i>Non-steroidal anti-inflammatory</i>		
Ketorolac tromethamine	0.5% solution	q.i.d.
<i>Mast cell stabilizer</i>		
Cromolyn sodium	4.0% solution	q.i.d.
Lodoxamide tromethamine	0.1% solution	q.i.d.
Pemirolast potassium	0.1% solution	q.i.d.
Nedocromil sodium	2.0% solution	b.i.d.
<i>Antihistamine/ H<sub>1</sub> agonist</i>		
Emastadine difumarate	0.05% solution	q.i.d.
Levocabastine hydrochloride	0.05% suspension	q.i.d.
Azelastine hydrochloride	0.05% solution	b.i.d.
<i>Antihistamine/mast cell stabilizer</i>		
Olopatadine hydrochloride	0.1% solution	b.i.d.
Ketotifen fumarate	0.025% solution	b.i.d.

**b. Bacterial Conjunctivitis**

The ideal method of treating bacterial conjunctivitis is to identify the causative organism and initiate specific antimicrobial treatment known to be effective against the offending organism. Table 7 lists the commonly available topical antimicrobial drugs and the spectrum of activity and recommended dosage for each. In the absence of a culture or smear, the etiologic agent should be considered in the context of the patient's age, environment, and related ocular findings. In most cases, a broad-spectrum topical antibiotic is the treatment of choice.<sup>10</sup> Although most cases of bacterial conjunctivitis are self-limited, treatment with effective antibiotics can lessen the patient's symptoms, decrease the duration of the infection, and reduce the chances of its recurrence.<sup>70</sup>



**Table 7**  
**Commonly Used Antimicrobial Agents and Their Spectrum of Activity**

Type of Antimicrobial Agent	Spectrum of Activity (Genus or Species)	Concentration	Frequency of Administration
Aminoglycoside (gentamicin/tobramycin)	<u>Staphylococcus</u> , <u>Streptococcus</u> , <u>Haemophilus</u> , <u>Proteus</u> , <u>Escherichia coli</u> , <u>Moraxella</u> , <u>Pseudomonas</u>	0.3%	q.2h. to q.i.d.
Bacitracin zinc	<u>Staphylococcus</u> , <u>Streptococcus</u> , <u>Neisseria</u>	500 U/g (ointment)	q.h.s. to q.i.d.
Chloramphenicol	<u>Staphylococcus</u> , <u>Haemophilus</u> , <u>Proteus</u>	1.0% (ointment) 0.5% (solution)	q.2h. to q.i.d.
Erythromycin	<u>Staphylococcus</u> , <u>Streptococcus</u> , <u>Neisseria</u> , <u>Haemophilus</u>	0.5% (ointment)	q.h.s. to q.i.d.
Fluoroquinolone (ciprofloxacin, ofloxacin, levofloxacin)	<u>Staphylococcus</u> , <u>Streptococcus</u> , <u>Haemophilus</u> , <u>Pseudomonas</u>	0.3%–0.5%	q.2h. to q.i.d.
Polymyxin B/neomycin	<u>Staphylococcus</u> , <u>Proteus</u> , <u>Moraxella</u> , <u>Pseudomonas</u>	16,250 U; 3.5 mg/ml	q.i.d.
Polymyxin B/trimethoprim sulfate	<u>Staphylococcus</u> , <u>Streptococcus</u> , <u>Proteus</u> , <u>Escherichia coli</u> , <u>Haemophilus</u>	10,000 U; 1 mg/ml	q.3h.
Sodium sulfacetamide	<u>Streptococcus</u> , <u>Haemophilus</u> , <u>Moraxella</u>	10%–30%	q.2h. to q.i.d.
Sulfisoxazole diolamine	<u>Streptococcus</u> , <u>Haemophilus</u> , <u>Moraxella</u>	4.0%	q.i.d.
Tetracycline	<u>Staphylococcus</u> , <u>Neisseria</u> , <u>Escherichia coli</u>	1.0%	q.2h. to q.i.d.

Hyperacute conjunctivitis requires special consideration because of potential blinding from inadequately treated gonococcal infections. Conjunctival smears and cultures should be obtained before beginning treatment. The administration of systemic antibiotics that are effective against the identified organisms should be started immediately. Saline lavage may be beneficial in removing purulent discharge. In the case of gonococcal infection, the Centers for Disease Control and Prevention (CDC) recommends the administration of a single dose of intramuscular ceftriaxone.<sup>71</sup> Although the CDC does not recommend topical treatment, practitioners may wish to consider the addition of a topical fluoroquinolone as adjunctive therapy. Patients should also be evaluated for co-infection with other sexually transmitted diseases. Care of the patient with sexually transmitted disease should be coordinated with the patient's primary care physician.

**c. Viral Conjunctivitis**

Most viral conjunctivitis is related to adenoviral infection; however, no antiviral agent has been demonstrated to be effective in treating these infections.<sup>72</sup> Likewise, topical NSAIDs have shown no benefit in reducing viral replication, decreasing the incidence of subepithelial infiltrates, or alleviating patients' symptoms.<sup>73,74</sup> Supportive therapy includes time-honored treatment options: cold compresses, lubricants, and ocular decongestants.

Topical antibiotics are not routinely used to treat viral conjunctivitis, unless there is evidence of secondary bacterial infection. The risk of toxic and allergic reactions may outweigh the potential benefit of antibiotic use. The use of steroids in the management of adenoviral conjunctivitis remains controversial. Because of the potential side effects of topical ophthalmic corticosteroids, practitioners may wish to limit the use of these agents to patients who are significantly symptomatic or who develop visual loss from inflammatory keratitis.<sup>75</sup>

The treatment of herpes simplex conjunctivitis may include the use of antiviral agents such as trifluridine, although there is no evidence that this therapy results in a lower incidence of recurrent disease or keratitis.<sup>75</sup> Supportive therapy, including lubricants and cold compresses, which may

be as effective as antiviral drugs, eliminates the potential for toxic side effects.<sup>76</sup> Topical steroids are specifically contraindicated for treating herpes simplex conjunctivitis.

Herpes zoster conjunctivitis treatment includes the use of topical antibiotic/steroid combinations to reduce the risk of secondary bacterial infection and decrease the inflammatory response.<sup>19</sup> In contrast with their effect on herpes simplex infections, topical steroids do not exacerbate herpes zoster infections. In addition to topical therapy, systemic antiviral treatment reduces the duration of both viral shedding and post-herpetic neuralgia. To be most effective in reducing the duration of post-herpetic neuralgia, systemic antiviral therapy should be started within 72 hours of the first signs of herpes zoster infection.<sup>77</sup>

**d. Chlamydial Conjunctivitis**

The primary treatment for adult inclusion conjunctivitis is systemic antibiotics; topical therapy alone is inadequate. The recommended systemic treatment, based on the patient's age, weight, and medical history, is either of two equally efficacious options:<sup>71,78</sup> a single dose of azithromycin 1 g or doxycycline 100 mg twice daily for 7 days. Azithromycin is the preferred treatment, especially when patient compliance is a potential problem.<sup>21</sup> Patients' sexual partners should also be evaluated for the presence of infection and their treatment initiated as indicated. In cases of chlamydial infection affecting preadolescent children, the clinician should consider the possibility that sexual abuse has occurred.

**e. Contact Lens-Related Conjunctivitis**

The primary treatment of contact lens-related conjunctivitis involves discontinuing contact lens wear and determining the underlying etiologic mechanism for the conjunctivitis. Solution allergies, hypoxic conditions, GPC, bacterial infections, or contact lens-related trauma should be identified and corrected prior to resuming contact lens wear.

**f. Mechanical Conjunctivitis**

Removal of the offending trauma-inducing agent (e.g., misdirected lash, exposed suture) and subsequent lubrication usually constitute adequate treatment of mechanical conjunctivitis. In addition to lubricants, prophylactic broad-spectrum antibiotic ophthalmic drops should be considered in cases of significant epithelial disruption (staining) until the epithelial defects have resolved.

**g. Traumatic Conjunctivitis**

The treatment of traumatic conjunctivitis depends upon the nature of the trauma. Conjunctival abrasions may be treated with topical antibiotics, cycloplegia, and pressure patching. Topical antibiotics may be used in cases of epithelial disruption, and oral analgesics should be prescribed for pain as needed. The initial treatment of chemical injuries should include copious irrigation with normal saline or balanced salt solution until the pH of the conjunctival cul-de-sac has returned to normal. Chemical injuries, particularly alkali burns, have the potential for significant ocular morbidity and require aggressive management.

**h. Toxic Conjunctivitis**

Most cases of toxic conjunctivitis result from overuse of topical medications or cosmetics, or both. Occasionally, environmental exposure to noxious agents results in toxic conjunctivitis. Treatment involves identifying and removing the offending agent. Molluscum lesions on the lids should be excised. Symptomatic patients may benefit from using cold compresses or topical ophthalmic antibiotic/corticosteroid combinations, or both. The treatment of toxic conjunctivitis from overuse of topical preparations should be to stop all topical medications initially, when possible, and use preservative-free topical lubricants 4–8 times a day for 3–5 days. Patients who show no sign of clinical improvement after this treatment should be re-evaluated for another underlying cause.



**i. Neonatal Conjunctivitis**

The optometrist should consider co-managing neonatal conjunctivitis with a pediatrician, neonatologist, or pediatric infectious disease specialist. Treatment should begin immediately upon diagnosis. Initially, antimicrobial therapy should be directed at the organism identified in conjunctival smears. Table 8 summarizes the therapeutic approaches to the most common causes of neonatal conjunctivitis.

**Table 8  
Treatment of Neonatal Conjunctivitis\***

<b>Etiology</b>	<b>Systemic Agent</b>	<b>Topical Agent</b>
Gonococcal	Ceftriaxone (25–50 mg/kg) IV or IM in a single dose not to exceed 125 mg	Inadequate if used alone; unnecessary with systemic treatment
Herpes simplex	Acyclovir (30–60 mg/kg/day) IV or IM q.8h. for 10–14 days	Inadequate if used alone; unnecessary with systemic treatment
Chlamydial	Erythromycin (50 mg/kg/day) orally, divided into 4 doses daily for 10–14 days	Inadequate if used alone; unnecessary with systemic treatment
Chemical	None	Irrigation of significant discharge

\*Based on Centers for Disease Control and Prevention. 1998 Guidelines for Treatment of Sexually Transmitted Diseases. MMWR 1998; 47(no.RR-1):1-118.

**j. Parinaud Oculoglandular Syndrome**

Because the vast majority of cases are self-limiting, the aim of therapy for Parinaud oculoglandular syndrome is symptomatic relief of preauricular lymphadenopathy. The application of a mild topical vasoconstrictor/lubricant and warm soaks of the inflamed preauricular area are generally sufficient. Biopsy of conjunctival granuloma not only provides diagnostic information regarding the etiologic agent but may have therapeutic benefits;<sup>23</sup> however, this procedure is indicated only in severe cases.

**k. Phlyctenular Conjunctivitis**

The treatment of phlyctenular conjunctivitis is directed at the underlying mechanism, to eradicate the sensitizing agent when possible. This generally means eliminating chronic lid disease, which serves as a reservoir for *Staphylococcus aureus*. The conjunctivitis itself responds favorably to the topical use of an antibiotic/corticosteroid combination applied 4 times a day for several days and then tapered. When there is associated blepharitis or other dermatologic disorder (e.g., acne rosacea), oral doxycycline can be helpful. In children younger than 8 years of age or in pregnant women, erythromycin should be used rather than doxycycline.<sup>79</sup> When the patient's history is significant for potential mycobacterium tuberculosis exposure, the practitioner should consider and rule out tuberculosis as the etiologic agent.

**l. Secondary Conjunctivitis**

The management of secondary conjunctivitis requires identification and treatment of the underlying ocular or systemic conditions. Patients who develop conjunctivitis as a manifestation of systemic disease should be evaluated and co-managed with an appropriate medical specialist.

**3. Patient Education**

Effective management of conjunctivitis requires appropriate patient education. Thorough education should help relieve the patient's anxiety about the condition and may increase his or her compliance with therapy.





Good patient education is also crucial for preventing the spread of infectious conjunctivitis, which in many cases is highly contagious. Live adenovirus particles have been recovered from the tears of infected individuals up to 14 days after the onset of infection.<sup>80</sup> Patient education concerning proper hygiene during the infection can help break the chain of epidemic transmission. The practitioner should stress the importance of frequent hand washing by patients and family members, of using separate linens, towels, and washcloths, and of avoiding direct contact with infected material or individuals.

#### **4. Prognosis and Follow-up**

Once conjunctivitis has been diagnosed and treatment has been initiated, the patient requires follow-up care. The frequency of follow-up visits varies with the severity of the condition, the diversity of etiologies considered, and the potential for ocular morbidity. Follow-up should be designed for careful monitoring of disease progression and verification that the selected treatment regime is effective. Alteration of therapy, when needed, as well as recognition of adverse side effects and re-evaluation of the condition and its response to treatment at regular intervals, are integral to successful patient management (Figure 3)



## CONCLUSION

Conjunctivitis is a common, multifaceted disease process that has a variety of etiologies and clinical features, and requires a variety of treatments. Professional care is needed for accurate diagnosis and effective therapeutic intervention. Optometrists play an integral role in the diagnosis, treatment, and management of conjunctivitis.

## III. References

1. Rothenberg ME, Owen WF Jr, Stevens RL. Ocular allergy. Mast cells and eosinophils. *Int Ophthalmol Clin* 1988; 28:267-74.
2. Hogan MJ. Atopic keratoconjunctivitis. *Am J Ophthalmol* 1953; 36:937-47.
3. Donschik PC, Ehlers WH. Ocular allergy. In: Smolin G, Thoft RA, eds. *The cornea*, 3rd ed. Boston: Little, Brown & Co, 1994:347-64.
4. Smolin G, O'Connor GR. *Ocular immunology*, 2nd ed. Boston: Little, Brown & Co, 1986:158.
5. Neumann E, Gutmann MJ, Blumenkrantz N, Michaelson IC. A review of 400 cases of vernal conjunctivitis. *Am J Ophthalmol* 1959; 47:166-72.
6. Arrfa RC. *Grayson's diseases of the cornea*, 4th ed. St. Louis: Mosby-Year Book, 1997:160.
7. Friedlaender MH. Conjunctivitis of allergic origin: clinical presentation and differential diagnosis. *Surv Ophthalmol* 1993; 38(suppl):105-14.
8. Jackson WB. Differentiating conjunctivitis of diverse origins. *Surv Ophthalmol* 1993; 38(suppl):91-104.
9. Arrfa RC. *Grayson's diseases of the cornea*, 4th ed. St Louis: Mosby-Year Book, 1997:138.
10. Mannis MJ. Bacterial conjunctivitis. In: Tasman W, Jaeger EA, eds. *Duane's clinical ophthalmology*, vol 4. Philadelphia: JB Lippincott, 1990:1-7.
11. Ostler HB. *Diseases of the external eye and adnexa*. Baltimore: Williams & Wilkins, 1993:73.

References 43

12. Wan WL, Farkas GC, May WN, Robin JB. The clinical characteristics and course of adult gonococcal conjunctivitis. *Am J Ophthalmol* 1986; 102:575-83.
13. Hierholzer JC, Wigand R, Anderson LJ, et al. Adenoviruses from patients with AIDS: a plethora of serotypes and a description of five new serotypes of subgenus D (types 43-47). *J Infect Dis* 1988; 158:804-13.
14. Gordon JS. Adenoviral and other nonherpetic viral diseases. In: Smolin G, Thoft RA, eds. *The cornea*, 3rd ed. Boston: Little, Brown & Co, 1994:215-27.
15. Ford E, Nelson KE, Warren D. Epidemiology of epidemic keratoconjunctivitis. *Epidemiol Rev* 1987; 9:244-61.
16. Arrfa RC. *Grayson's diseases of the cornea*, 4th ed. St. Louis: Mosby-Year Book, 1997:286.
17. Smith IW, Peutherer JF, MacCallum FO. The incidence of Herpesvirus hominis antibody in the population. *J Hyg (Lond)* 1967; 65:395-408.
18. Burgoon CF, Burgoon JS, Baldrige GD. The natural history of herpes zoster. *JAMA* 1957; 164:265-7.
19. Karbassi M, Raizman MB, Schuman JS. Herpes zoster ophthalmicus. *Surv Ophthalmol* 1992; 36:395-410.
20. Washington AE, Johnson RE, Sanders LL Jr. Chlamydia trachomatis infections in the United States. What are they costing us? *JAMA* 1987; 257:2070-72.
21. Whitcher JP. Chlamydial keratitis and conjunctivitis. In: Smolin G, Thoft RA, eds. *The cornea*, 3rd ed. Boston: Little, Brown & Co, 1994:277-293.

44 Conjunctivitis

22. Rothenberg R. Ophthalmia neonatorum due to Neisseria gonorrhoeae: prevention and treatment. *Sex Transm Dis* 1979; 6(2 suppl ):187-91.
23. Isenberg SJ, Apt L, Wood M. A controlled trial of povidone-iodine as prophylaxis against ophthalmia neonatorum. *N Engl J Med* 1995; 332(9):562-6.
24. Chen JY. Prophylaxis of ophthalmia neonatorum: comparison of silver nitrate, tetracycline, erythromycin and no prophylaxis. *Pediatr Infect Dis J* 1992; 11(12):1026-30.
25. Chin GN. Parinaud oculoglandular conjunctivitis. In: Tasman W, Jaeger EA, eds. *Duane's clinical ophthalmology*, vol 4. Philadelphia: JB Lippincott, 1994:1-7.
26. Davis PL, Watson PI. Experimental conjunctival phlyctenulosis. *Can J Ophthalmol* 1970; 4:183.
27. Arrfa RC. *Grayson's diseases of the cornea*, 4th ed. St Louis: Mosby-Year Book, 1997:512.
28. Helm CT, Holland GN. Ocular tuberculosis. *Surv Ophthalmol* 1993; 38:229-56.
29. Ganley JP, Roberts J. Eye conditions and related need for medical care among persons 1-74 years of age, United States 1971-72. *Vital and health statistics, series 11, no. 228*, DHHS publication no. (PHS) 83-1678. Washington, DC: U.S. Government Printing Office, March 1983.
30. Duke-Elder SS. *System of ophthalmology*, vol VIII, part 1. St. Louis: CV Mosby, 1965:3.
31. Feldman RB, Stern GA, Hood CI. Chromobacterium violaceum infection of the eye. A report of two cases. *Arch Ophthalmol* 1984; 102:711-3.

#### References 45

32. Feduckowicz HB. External infections of the eye, 3rd ed. Norwalk, CT: Appleton-Century-Crofts, 1985:57.
33. Ostler HB. Diseases of the external eye and adnexa. Baltimore: Williams & Wilkins, 1993:74.
34. Beem MO, Saxon EM. Respiratory-tract colonization and a distinctive pneumonia syndrome in infants infected with Chlamydia trachomatis. N Engl J Med 1977; 296:306-10.
35. Harrison JR, English MG, Lee CK, Alexander ER. Chlamydia trachomatis infant pneumonitis: comparison with matched controls and other infant pneumonitis. N Engl J Med 1978; 298:702-8.
36. Londer L, Nelson DL. Orbital cellulitis due to Haemophilus influenzae. Arch Ophthalmol 1974; 91:89-91.
37. Feingold M, Gellis SS. Cellulitis due to Haemophilus influenza type B. N Engl J Med 1965; 272:788-9.
38. Gordon YJ, Gordon RY, Romanowski E, Araullo-Cruz TP. Prolonged recovery of desiccated adenoviral serotypes 5, 8, and 19 from plastic and metal surfaces in vitro. Ophthalmology 1993; 100:1835-9.
39. Primary Care and Ocular Disease Committee, American Optometric Association. Infection control: guidelines for the optometric practice. J Am Optom Assoc 1993; 64:853-61.
40. Bialasiewicz AA, Jahn GJ. Evaluation of diagnostic tools for adult chlamydial keratoconjunctivitis. Ophthalmology 1987; 94:532-7.
41. Jaanus SD, Cheetham JK, Leshner GA. Anti-inflammatory drugs. In: Bartlett JD, Jaanus SD, eds. Clinical ocular pharmacology, 4th ed. Boston: Butterworths, 2001:265-266.

#### 46 Conjunctivitis

42. Jaanus SD, Cheetham JK, Leshner GA. Anti-inflammatory drugs. In: Bartlett JD, Jaanus SD, eds. Clinical ocular pharmacology, 4th ed. Boston: Butterworths, 2001:273-276.
43. Friedlaender MH, Howes J. A double-masked, placebo-controlled evaluation of the efficacy and safety of loteprednol etabonate in the treatment of giant papillary conjunctivitis. The Loteprednol Etabonate Giant Papillary Conjunctivitis Study Group I. Am J Ophthalmol 1997; 123(4):455-64.
44. Dell SJ, Shulman DG, Lowry GM, Howes J. A controlled evaluation of the efficacy and safety of loteprednol etabonate in the prophylactic treatment of seasonal allergic conjunctivitis. Loteprednol Allergic Conjunctivitis Study Group. Am J Ophthalmol 1997; 123(6):791-7.
45. Shulman DG, Lothringer LL, Rubin JM, et al. A randomized, double-masked, placebo-controlled parallel study of loteprednol etabonate 0.2% in patients with seasonal allergic conjunctivitis. Ophthalmology 1999; 106(2):362-9.
46. Novack GD, Howes J, Crockett RS, Sherwood MB. Change in intraocular pressure during long-term use of loteprednol etabonate. J Glaucoma 1998; 7(4):266-9.
47. Abelson MB, Allansmith MR, Friedlaender MH. Effects of topically applied ocular decongestant and antihistamine. Am J Ophthalmol 1980; 90:254-7.
48. Parys W, Blockhuys S, Janssens M. New trends in the treatment of allergic conjunctivitis. Doc Ophthalmol 1992; 82:353-60.
49. Giede-Tuch C, Westhoff M, Zarth A. Azelastine eye-drops in seasonal allergic conjunctivitis or rhinoconjunctivitis. A double-blind, randomized, placebo-controlled study. Allergy 1998; 53(9):857-62.

References 47

50. Secchi A, Leonardi A, Discepola M, et al. An efficacy and tolerance comparison of emedastine difumarate 0.05% and levocabastine hydrochloride 0.05%: reducing chemosis and eyelid swelling in subjects with seasonal allergic conjunctivitis. Emadine Study Group. *Acta Ophthalmol Scand Suppl* 2000 (230):48-51.
51. Secchi A, Ciprandi G, Leonardi A, et al. Safety and efficacy comparison of emedastine 0.05% ophthalmic solution compared to levocabastine 0.05% ophthalmic suspension in pediatric subjects with allergic conjunctivitis. Emadine Study Group. *Acta Ophthalmol Scand Suppl* 2000; (230):42-7.
52. Flach AJ. Cyclo-oxygenase inhibitors in ophthalmology. *Surv Ophthalmol* 1992; 36:259-84.
53. Ballas Z, Blumenthal M, Tinkelman DG, et al. Clinical evaluation of ketorolac tromethamine 0.5% ophthalmic solution for the treatment of seasonal allergic conjunctivitis. *Surv Ophthalmol* 1993; 38(suppl):141-8.
54. Tauber J, Raizman MB, Ostroy CS, et al. A multicenter comparison of the ocular efficacy and safety of diclofenac 0.1% solution with that of ketorolac 0.5% solution in patients with acute seasonal allergic conjunctivitis. *J Ocul Pharmacol Ther* 1998; 14(2):137-45.
55. Melamed J, Schwartz RH, Blumenthal MN, Zeitz HJ. Efficacy and safety of nedocromil sodium 2% ophthalmic solution b.i.d. in the treatment of ragweed seasonal allergic conjunctivitis. *Allergy Asthma Proc* 2000; 21(4):235-9.
56. Verin PH, Dicker ID, Mortemousque B. Nedocromil sodium eye drops are more effective than sodium cromoglycate eye drops for the long-term management of vernal keratoconjunctivitis. *Clin Exp Allergy* 1999; 29(4):529-36.

48 Conjunctivitis

57. Tabbara KF, al-Kharashi SA. Efficacy of nedocromil 2% versus fluorometholone 0.1%: a randomized, double masked trial comparing the effects on severe vernal keratoconjunctivitis. *Br J Ophthalmol* 1999; 83(2):180-4.
58. Fahy GT, Easty DL, Collum LM, et al. Randomised double-masked trial of lodoxamide and sodium cromoglycate in allergic eye disease. A multicentre study. *Eur J Ophthalmol* 1992; 2(3):144-9.
59. Avunduk AM, Avunduk MC, Kapicioglu Z, et al. Mechanisms and comparison of anti-allergic efficacy of topical lodoxamide and cromolyn sodium treatment in vernal keratoconjunctivitis. *Ophthalmology* 2000; 107(7):1333-7.
60. Allansmith MR, Ross RN. Giant papillary conjunctivitis. In: Fraunfelder FT, Roy FH, eds. *Current ocular therapy* 3. Philadelphia: WB Saunders, 1990:411-3.
61. Abelson MB. Evaluation of olopatadine, a new ophthalmic antiallergic agent with dual activity, using the conjunctival allergen challenge model. *Ann Allergy Asthma Immunol* 1998; 81(3):211-8.
62. Yanni JM, Miller ST, Gamache DA, et al. Comparative effects of topical ocular anti-allergy drugs on human conjunctival mast cells. *Ann Allergy Asthma Immunol* 1997; 79(6):541-5.
63. Deschenes J, Discepola M, Abelson M. Comparative evaluation of olopatadine ophthalmic solution (0.1%) versus ketorolac ophthalmic solution (0.5%) using the provocative antigen challenge model. *Acta Ophthalmol Scand Suppl* 1999; (228):47-52.
64. Berdy GJ, Spangler DL, Bensch G, et al. A comparison of the relative efficacy and clinical performance of olopatadine hydrochloride 0.1% ophthalmic solution and ketotifen fumarate 0.025% ophthalmic solution in the conjunctival antigen challenge model. *Clin Ther* 2000; 22(7):826-33.

References 49

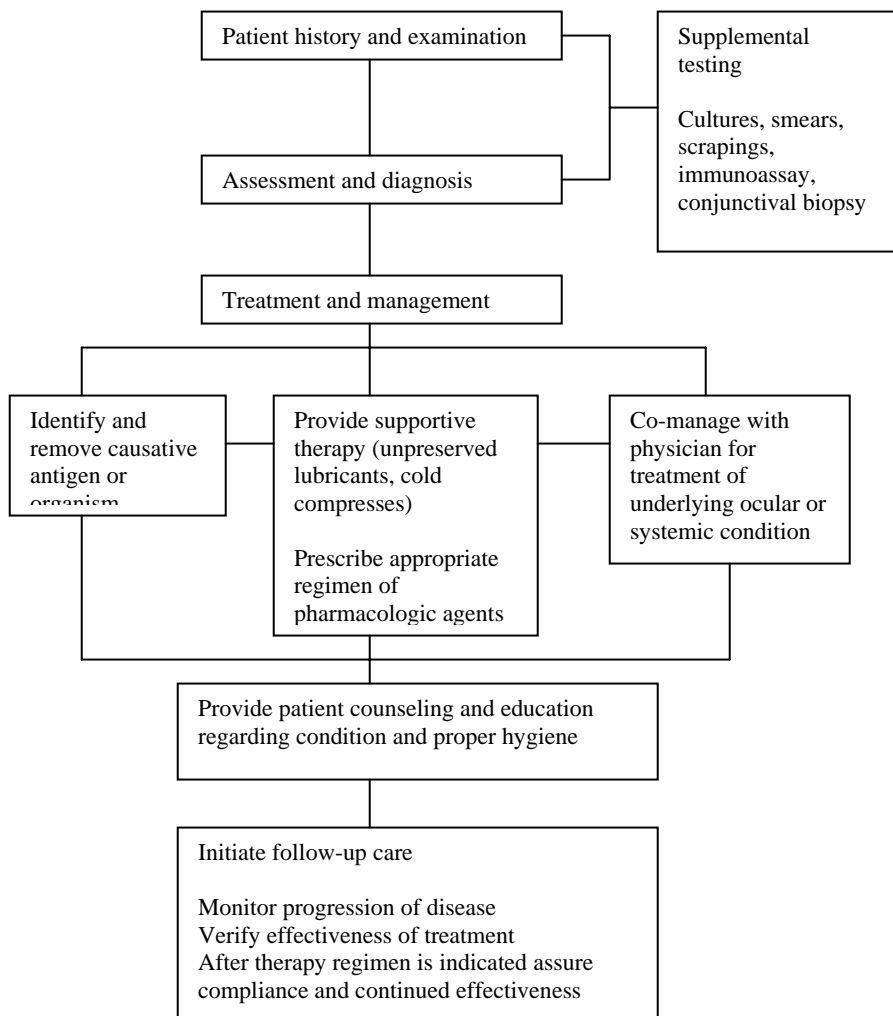
65. Aguilar AJ. Comparative study of clinical efficacy and tolerance in seasonal allergic conjunctivitis management with 0.1% olopatadine hydrochloride versus 0.05% ketotifen fumarate. *Acta Ophthalmol Scand Suppl* 2000; 230:52-5.
66. Hoang-Xuan T, Prisant O, Hannouche D, Robin H. Systemic cyclosporine A in severe atopic keratoconjunctivitis. *Ophthalmology* 1997; 104(8):1300-5.
67. Hingorani M, Moodaley L, Calder VL, et al. A randomized, placebo-controlled trial of topical cyclosporin A in steroid-dependent atopic keratoconjunctivitis. *Ophthalmology* 1998; 105(9):1715-20.
68. Mendicute J, Aranzasti C, Eder F, et al. Topical cyclosporin A 2% in the treatment of vernal keratoconjunctivitis. *Eye* 1997; 11 (Pt. 1):75-8.
69. Allansmith MR, Ross RN. Allergic conjunctivitis. In: Fraunfelder FT, Roy FH, eds. *Current ocular therapy 3*. Philadelphia: WB Saunders, 1990:400-2.
70. Jackson WB, Easterbrook WM, Connolly WE, Leers WD. Treatment of blepharitis and blepharoconjunctivitis: comparison of gentamycin-bethamethasone, gentamycin alone and placebo. *Can J Ophthalmol* 1982; 17:153-6.
71. Centers for Disease Control and Prevention. 1998 guidelines for treatment of sexually transmitted diseases. *MMWR* 1998; 47(no. RR-1):1-111.
72. Feduckowicz HB. *External infections of the eye*, 3rd ed. Norwalk, CT: Appleton-Century-Crofts, 1985:153.
73. Shiuey Y, Ambati BK, Adamis AP. A randomized, double-masked trial of topical ketorolac versus artificial tears for treatment of viral conjunctivitis. *Ophthalmology* 2000; 107(8):1512-7.

50 Conjunctivitis

74. Gordon YJ, Araullo-Cruz T, Romanowski EG. The effects of topical nonsteroidal anti-inflammatory drugs on adenoviral replication. *Arch Ophthalmol* 1998; 116(7):900-5.
75. Dawson CR, Sheppard JD. Follicular conjunctivitis. In: Tasman W, Jaeger EA, eds. *Duane's clinical ophthalmology*, vol 4. Philadelphia: JB Lippincott, 1990:1-26.
76. Ostler HB. *Diseases of the external eye and adnexa*. Baltimore: Williams & Wilkins, 1993:96.
77. Tyring S, Barbarash RA, Nahlik JE, et al. Famciclovir for the treatment of acute herpes zoster: effects on acute disease and postherpetic neuralgia. A randomized, double-blind, placebo-controlled trial. Collaborative Famciclovir Herpes Zoster Study Group. *Ann Intern Med* 1995; 123(2):89-96.
78. Stamm WE. Azithromycin in the treatment of uncomplicated genital chlamydial infections. *Am J Med* 1991; 91(3A):19S-22S.
79. Culbertson WW, Huang AJ, Mandelbaum SH, et al. Effective treatment of phlyctenular keratoconjunctivitis with oral tetracycline. *Ophthalmology* 1993; 100:1358-66.
80. Dawson CR, Hanna L, Wood TR, Despain R. Adenovirus type 8 keratoconjunctivitis in the United States. 3. Epidemic, clinical and microbiologic features. *Am J Ophthalmol* 1970; 69:473-80.

IV. APPENDIX

**Figure 1**  
**Optometric Management of the Patient**  
**With Conjunctivitis:**  
**A Brief Flowchart**



**Figure 2**  
**Procedures for Obtaining Conjunctival Cultures, Smears,**  
**and Scrapings**

**Conjunctival Cultures**

A specimen is obtained from the conjunctival surface with a sterile instrument. A sterile swab is gently passed several times over the lower tarsal and fornix conjunctiva. The swab may be moistened with thioglycolate broth or unpreserved sterile saline or sterile water. Both eyes should be cultured even in unilateral processes to aid in the interpretation of "positive" cultures. Immediate inoculation on culture media is preferred to the use of transport media and subsequent inoculation. Routine cultures should be obtained on the following media: blood agar, chocolate agar, thioglycolate broth (anaerobic), and Sabouraud's agar (fungal).

**Conjunctival Smears**

Specimens for conjunctival smears are obtained in the same general way as for cultures. The instrument should be passed over the lower conjunctival fornix several times and care should be exercised to avoid touching the lid margin. The material obtained is then placed on a clean glass slide and fixed. A variety of stains can be applied and the specimen is then examined under a microscope. Stains most commonly used include: Gram stain or Wright stain.

**Conjunctival Scrapings**

Under topical anesthesia, the area of the conjunctiva most involved with the disease process is sampled. After swabbing away excess discharge, a sterile spatula is used to gently scrape the conjunctival surface. Scraping should be firm enough to recover material but should not elicit bleeding. Recovered material is immediately placed on a clean glass slide and fixed with methyl alcohol. Stains commonly used on conjunctival scrapings are Giemsa and Papanicolaou.



**Figure 3**  
**Frequency and Composition of Evaluation and Management Visits for Conjunctivitis**

Condition	Frequency of Follow-up	History	Visual Acuity
Allergic conjunctivitis	Mild: Every 5-7 days Moderate: Every 3-5 days Severe: Every 1-3 days	Yes	Yes
Bacterial conjunctivitis	Mild: Every 5-7 days Moderate: Every 3-5 days Severe: Every 1-3 days	Yes	Yes
Viral Conjunctivitis	Mild: Every 5-7 days Moderate: Every 3-5 days Severe: Every 1-3 days	Yes	Yes
Chlamydial conjunctivitis	Mild: Every 5-7 days Moderate: Every 3-5 days Severe: Every 1-3 days	Yes	Yes

**Figure 3 (Continued)**

Condition	Slit Lamp Biomicroscopy	Ophthalmoscopy	Management Plan
Allergic conjunctivitis	Yes	As indicated	Identify/remove allergen. Prescribe unpreserved lubricants, cold compresses, topical pharmaceuticals, systemic antihistamines. Educate patient
Bacterial conjunctivitis	Yes	As indicated	Identify organism and specific antimicrobial agent. Hyperacute form: obtain smears and cultures, do saline lavage. Prescribe topical and/or systemic antibiotics. Obtain consultation for evaluation and treatment of underlying systemic condition. Educate patient.
Viral Conjunctivitis	Yes	As indicated	Prescribe cold compresses, lubricants, ocular decongestants, and topical pharmacologic agents as appropriate. Educate patient.
Chlamydial conjunctivitis	Yes	As indicated	Prescribe systemic antibiotic. Obtain consultation for evaluation and treatment of underlying systemic condition. Educate patient.

**Figure 4**  
**ICD-9-CM Classification of Conjunctivitis**

Disorders of conjunctiva	372
<i>Excludes: keratoconjunctivitis (370.3–370.4)</i>	
Acute conjunctivitis	372.0
Acute conjunctivitis, unspecified	372.00
Serous conjunctivitis, except viral	372.01
<i>Excludes: viral conjunctivitis NOS (077.9)</i>	
Acute follicular conjunctivitis	372.02
Conjunctival folliculosis NOS	
<i>Excludes: conjunctivitis:</i>	
<i>adenoviral (acute follicular) (077.3)</i>	
<i>epidemic hemorrhagic (077.4)</i>	
<i>inclusion (077.0)</i>	
<i>Newcastle (077.8)</i>	
<i>epidemic keratoconjunctivitis (077.1)</i>	
<i>pharyngoconjunctival fever (077.2)</i>	
Other mucopurulent conjunctivitis	372.03
Catarrhal conjunctivitis	
<i>Excludes: blennorrhea neonatorum (gonococcal) (098.40)</i>	
<i>neonatal conjunctivitis (771.6)</i>	
<i>ophthalmia neonatorum NOS (771.6)</i>	
Pseudomembranous conjunctivitis	372.04
Membranous conjunctivitis	
<i>Excludes: diphtheritic conjunctivitis (032.81)</i>	
Acute atopic conjunctivitis	372.05
Chronic conjunctivitis	372.1
Chronic conjunctivitis, unspecified	372.10

Simple chronic conjunctivitis	372.11
Chronic follicular conjunctivitis	372.12
Vernal conjunctivitis	372.13
Other chronic allergic conjunctivitis	372.14
Parasitic conjunctivitis	372.15
<i>Code first: underlying disease, as</i>	
<i>filariasis (125.0–125.9)</i>	
<i>mucocutaneous leishmaniasis (085.5)</i>	
Blepharoconjunctivitis	372.2
Blepharoconjunctivitis, unspecified	
Angular blepharoconjunctivitis	372.20
Contact blepharoconjunctivitis	372.21
Contact blepharoconjunctivitis	372.22
Other and unspecified conjunctivitis	372.3
Conjunctivitis, unspecified	
Rosacea conjunctivitis	372.30
<i>Code first: underlying rosacea dermatitis (695.3)</i>	
Conjunctivitis in mucocutaneous disease	372.31
<i>Code first: underlying disease, as</i>	
erythema multiforme (695.1)	372.33
Reiter's disease (099.3)	
<i>Excludes: ocular pemphigoid (694.61)</i>	
Other	372.39
Certain types of keratoconjunctivitis	370.3
Phlyctenular keratoconjunctivitis	
Phlyctenulosis	370.31
<i>Use additional code for any associated tuberculosis (017.3)</i>	
Limbar and corneal involvement in vernal conjunctivitis	370.32
<i>Use additional code for vernal conjunctivitis (372.13)</i>	
Keratoconjunctivitis sicca, not specified as Sjogren's	370.33
<i>Excludes: Sjogren's syndrome (710.2)</i>	

Appendix 57

Exposure keratoconjunctivitis	370.34
Neurotrophic keratoconjunctivitis	370.35
Other and unspecified keratoconjunctivitis	370.4
Keratoconjunctivitis, unspecified	370.40
Superficial keratitis with conjunctivitis NOS	
Keratitis or keratoconjunctivitis in exanthema	370.44
Code first: underlying condition (050.0-052.9)	
Excludes: herpes simplex (054.43)	
herpes zoster (053.21)	
measles (055.71)	
Other	370.49
Excludes: epidemic keratoconjunctivitis (077.1)	
Trachoma	076
Excludes: late effect of trachoma (139.1)	
Initial Stage	
Trachoma dubium	
Active stage	
Granular conjunctivitis ( trachomatous)	
Trachomatous:	
follicular conjunctivitis	
pannus	
Other diseases of conjunctiva due to viruses and Chlamydiae	077
Excludes: ophthalmic complications of viral diseases classified elsewhere	
Inclusion conjunctivitis	077.0
Paratrachoma	
Swimming pool conjunctivitis	
Excludes: inclusion blennorrhoea (neonatal) (771.6)	
Epidemic keratoconjunctivitis	077.1
Shipyard eye	
Pharyngoconjunctival fever	077.2
Viral pharyngoconjunctivitis	

58 Conjunctivitis

Other adenoviral conjunctivitis	077.3
Acute adenoviral follicular conjunctivitis	
Epidemic hemorrhagic conjunctivitis	077.4
Apollo:	
conjunctivitis	
disease	
Conjunctivitis due to enterovirus type 70	
Hemorrhagic conjunctivitis (acute) (epidemic)	
Other viral conjunctivitis	077.8
Newcastle conjunctivitis	
Unspecified diseases of conjunctiva due to viruses and Chlamydiae	077.9
Viral conjunctivitis NOS	
Due to Chlamydiae	077.98
Due to viruses	077.99
Viral conjunctivitis NOS	



**Abbreviations of Commonly Used Terms**

AKC	-	Atopic keratoconjunctivitis
CDC	-	Centers for Disease Control and Prevention
EKC	-	Epidemic keratoconjunctivitis
FDA	-	Food and Drug Administration
GPC	-	Giant papillary conjunctivitis
IOP	-	Intraocular pressure
KP	-	Keratic precipitate
NSAID	-	Non-steroidal anti-inflammatory drug
PCF	-	Pharyngeal conjunctival fever
q.d.	-	Daily
q.h.s.	-	At bedtime; every night
q.i.d.	-	Four times daily
q._h.	-	Every _ hours
U	-	Unit

**Glossary\***

**Biomicroscopy** Examination of ocular tissue using a bright focal source of light with a slit of variable width and height and a binocular microscope with variable magnification.

**Conjunctiva** The mucous membrane extending from the eyelid margin to the corneal limbus, forming the posterior layer of the eyelids and the anterior layer of the eyeball.

**Conjunctivitis** Inflammation of the conjunctiva.

**Immunoassay** Detection and analysis of hormones or other substances by serological methods.

**Intraocular pressure (IOP)** The pressure within the eye, relative to the constant formation and drainage of aqueous humor.

**Neuro-ophthalmic screening** Evaluation of the relationship and disorders of the eyes and their associated parts to the central nervous system.

**Tonometry** A procedure for measurement of the pressure within the eye. Clinically, tonometry measures the intraocular tension.

**Visual acuity** The clearness of vision that depends upon the sharpness of focus of the retinal image and the integrity of the retina and visual pathway. It is expressed as the angle subtended at the anterior focal point of the eye by the detail of the letter or symbol recognized.

---

\* Sources:

Hofstetter HW, Griffin JR, Berman MS, Everson RW. Dictionary of visual science and related clinical terms, 5th ed. Boston, MA: Butterworth-Heinemann, 2000.

Grosvenor TP. Primary care optometry. Anomalies of refraction and binocular vision, 4th ed. Boston: Butterworth-Heinemann, 2002:3-112.

Stedman's medical dictionary, 27th ed. Baltimore: Williams & Wilkins, 2000.